Corrossion Cast of Air Sacs in Domestic Fowl

S. Sivagnanam, O.R. Sathyamoorthy and S. Paramasivan
Department of Veterinary Anatomy and Histology
Veterinary College and Research Institute, Orathanadu- 614625

The avian respiratory system is the most efficient among those of all air-breathing vertebrates and is unique in its basic structure (King and McLelland, 1984). Demonstration of air sacs in birds is difficult without a corrosion cast preparation because the air sacs are very thin membranous structures that are readily ruptured when a bird is dissected. Understanding the anatomy of air sacs in birds is also difficult with two dimensional diagrams. The latex rubber solution is used to demonstrate the air sacs in birds as it is cheaper and easily available in the market. Latex rubber solidifies with minimal shrinkage when it comes in contact with air.

Materials and methods

The carcass of a 72 week old cock was collected immediately after death. It was hanged with its head up in a isolated room. Upper third of the neck was incised and the trachea was pulled out. Air was sucked out as much as possible by inserting a collapsible tube, nearly half the length of the trachea. Then the free end of the tube was connected to a twenty milliltre syringe barrel loaded with 70% latex solution. Approximately 250 ml of latex solution was injected to fill the space within the lung and airsacs in the fowl (Tompsett, 1970).

Then the bird carcass was left undisturbed for three days. After three days, partially macerated bird carcass was dropped into a bucket containing water and left for complete natural maceration.

After two weeks the complete rubber cast of the lung and airsacs were carefully separated from the macerated mass and cleaned with soap water. Bones in the macerated mass were collected for mounting a skeleton. Then the cast was dried completely by keeping in hotair oven. Each type of airsac was given a unique colour for clear and easy demonstration to the students.

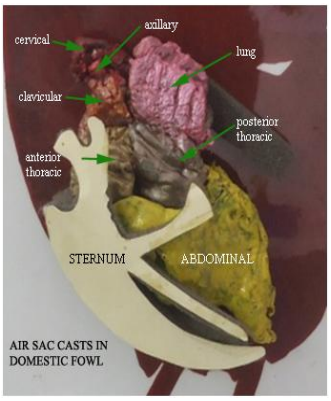

Fig. Air sac casts in domestic fowl

Preparing the display

Outline drawing of a domestic fowl was taken a colour print on a A3 board. A three dimensional model of a sternum of birds was made with sponge proportionate to the drawing and was attached in appropriate part of the drawing. The latex cast of lung and airsacs was placed over the model sternum by how it can easily be demonstrated. The colours used over the airsac casts were again painted in small

squares below the display so as to label them their proper names.

Results and discussion

Most avian species have four paired air sacs and one unpaired air sac (Nickel *et al.,* 1977). By this method we demonstrated five paired airsacs (cervical, axillary, anterior thoracic, posterior thoracic and abdominal) and a single (clavicular) airsac in domestic fowl. Extensive system of air sacs in birds allows continuous flow of fresh air through the pulmonary air capillaries at countercurrent to the blood circulation and throughout the respiratory cycle (McLelland, 1989).

The objective of this study was to provide a more detailed description of different airsacs in domestic fowl by preparing a latex rubber cast. The latex injected into the trachea was allowed to settle strictly by gravity and the carcass was left for maceration by hanging in air in order to promote polymerisation of the latex solution (Tompsett 1970)

Depending on the species, some of these air sacs can project complex systems of diverticula between muscles and into the subcutis and pneumatic bones of the trunk, pectoral and pelvic girdles, and limbs (O'Connor 2004). In the present study, complex system of diverticula of the airsacs was observed. It was found that the latex injected into the trachea easily fills most of the volume of the respiratory air sacs and their diverticula within the thoracic cavity. And further flows from the left and right ventrolateral regions of the clavicular air sac into the axillary regions. From the axillary region, the air diverticulum extends ventrally between the sternum and the pectoralis muscle and caudally along the lateral side of the trunk and along the medial side of the leg down to the distal region of the tibia which was in accordance with the findings of Daoust *et al.,* 2008. The latex cast of lung and airsacs placed over the model sternum and with different colours used over the airsac casts gave a clear understanding of the Anatomy of the airsacs in domestic fowl.

Summary

The bird airsacs are demonstrated by injecting latex through trachea followed by maceration of remaining tissues. An adult domestic fowl was sacrificed and hanged with its head up. Upper third of the neck was incised and the trachea ws pulled out. Air was sucked out as much as possible by inserting a collapsible tube nearly half the length of the trachea. The free end of the tube is inserted to a 20 ml syringe barrel loaded with 70% latex solution. Nearly 200 ml of latex was injected gently. The injected bird was hanged for one night. Then maceration of the bird was done to collect the cast of lung and airsacs and bones aswell. The air sacs were coloured differently for clear demonstration to the students

References

Daoust, P.Y., Dobbin, G.V., Ridlington, A. and Dawson, S.D. (2008). Descriptive anatomy of the subcutaneous air diverticula in the Northern Gannet, *Seabird* **21:** 64–76

King, A.S. and McLelland, J. (1984). Birds, their structure and function: 110–144. *Baillière Tindall, Toronto.* 2nd edn.

McLelland, J. (1989). Anatomy of the lungs and air sacs. Form and Function in Birds. Vol. **4:** 221–279. *Academic Press, Toronto.*

Nickel, R., Schummer, A. and Seiferie, E. (1977). The Anatomy of the Domestic Birds. Translated by W. G. Siller & P. A. L.Wight. *Springer-Verlag, New York.*

O'Connor, P.M. (2004). Pulmonary pneumaticity in the postcranial skeleton of extant Aves: a case study examining Anseriformes. *Journal of Morphology* 261: 141–161.

Tompsett, D.H. (1970). Anatomical Techniques: *E. & S. Livingstone, London*. 2nd edn. 259–265.